

Face and Neck Revitalization With Platelet-rich Plasma (PRP): Clinical Outcome in a Series of 23 Consecutively Treated Patients

Alessio Redaelli MD,^a Domenico Romano MD,^b Antonio Marcianò MD^c

^aA.M.I.Est, Milan, Italy; Research Area SIES (Italian Society of Aesthetic Medicine and Surgery), Florence, Italy; Padova University, Padova, Italy; Aesthetic Medicine, Visconti di Modrone Medical Center, Milan, Italy

^bPrivate practice, San Raffaele Medical Institute, Milan, Italy

^cPrivate practice, Messina, Italy

ABSTRACT

Background: Platelet-rich plasma (PRP) has long been known as an effective treatment in various surgical and medical fields. Face and neck revitalization with PRP is an application that is currently being explored. The aim of this paper is practical: to evaluate if there are real outcomes, benefits and side effects of a standardized injection protocol in a continuous series, without control groups.

Materials and Methods: In a three-month study, a consecutive series of 23 patients were treated with one session of injections with PRP every month from September 2008 to December 2008 (a total of three sessions). For blood management, a sterile Regen Lab[®] Kit was used. Patients received 4 mL of PRP, activated with calcium chloride, at standard injection points into face and neck skin. The study was documented with imaging before and after each session using a dermoscope, a digital camera, as well as a comprehensive state-of-the-art imaging system and dedicated medical imaging software.

Results: The results were evaluated one month after the last session (January 2009) by a special spider improvement score, a photograph score, a patient's satisfaction score and a doctor's satisfaction score. Finally, a definitive graduated score was calculated for each patient. Overall, the results were satisfactory. No serious and persistent side effects were detected.

Conclusion: Face and neck revitalization with PRP is a promising easy-to-perform technique in face and neck rejuvenation and scar attenuation. Further work needs to be carried out to investigate its exact mechanism of action.

INTRODUCTION

Platelet-rich plasma (PRP) has been used over the last several years as an effective treatment in various surgical and medical fields. In odontology,^{1,2,10,13} PRP has proven successful in gingival regeneration. In orthopedics, it is used in acceleration of improvements in bone fracture healing¹² and in articular cartilage repair.^{11,14} In traumatology, PRP is applied for the treatment of muscle strain injuries,⁶ (although definitive benefits in this area have not yet been confirmed), and interesting results have also been reported in the treatment of osteodegenerative diseases and in the management of patients with complex injuries.⁹ PRP is used in ulcer reconstruction⁷ and it has proven to be very effective in diabetic patients.³ The use of PRP has long been known in aesthetic medicine, as well^{4,5,8,10,15} although very few of the studies specifically attest to benefits in face and neck revitalization.

The aim of this study is absolutely practical: to illustrate the technique and the protocol used; to assess if there is a real outcome after the use of PRP in face and neck revitalization; to assess patients' impressions; to evaluate if side effects are present; and to specifically show the clinical evidence, in a consecutive series of 23 patients, without any control group. After this initial work, if good results are obtained, other, controlled studies will be conducted.

PATIENTS, MATERIALS AND METHODS

From September 2008 to December 2008, a consecutive series of 23 volunteers were enrolled and treated free of charge (average age 47, range 28–70). Patients read a study overview description, signed an informed consent and were counseled as to the benefits and possible adverse events of the treatment before the first session.

The protocol treatment, assessed in accordance with the scarce literature on the field, was a three-month study, with one session of injections with PRP every month (the first one administered in September 2008 and the last one in December 2008). The results were evaluated one month after the last session (January 2009).

For preparation of PRP, a sterile CE marked RegenLab[®] Kit was used, which was equipped with a butterfly 21G needle; vacutainer kit (to avoid direct contact with blood samples); calcium chloride; 2 mL syringe and 30G needles.

Preparation

After obtaining informed consent from the patients, a 16 mL blood sample was aspirated and collected in the sterile kit. Two special 8 mL test tubes were prepared. The test tubes were equipped with a separator, which centrifugally separates red

and white cells from platelet-rich plasma (Figure 1). Each test tube was centrifuged at 3,500 rpm for five minutes. Meanwhile, objective examinations were carried out, photographs were taken and a personal folder was filled in.

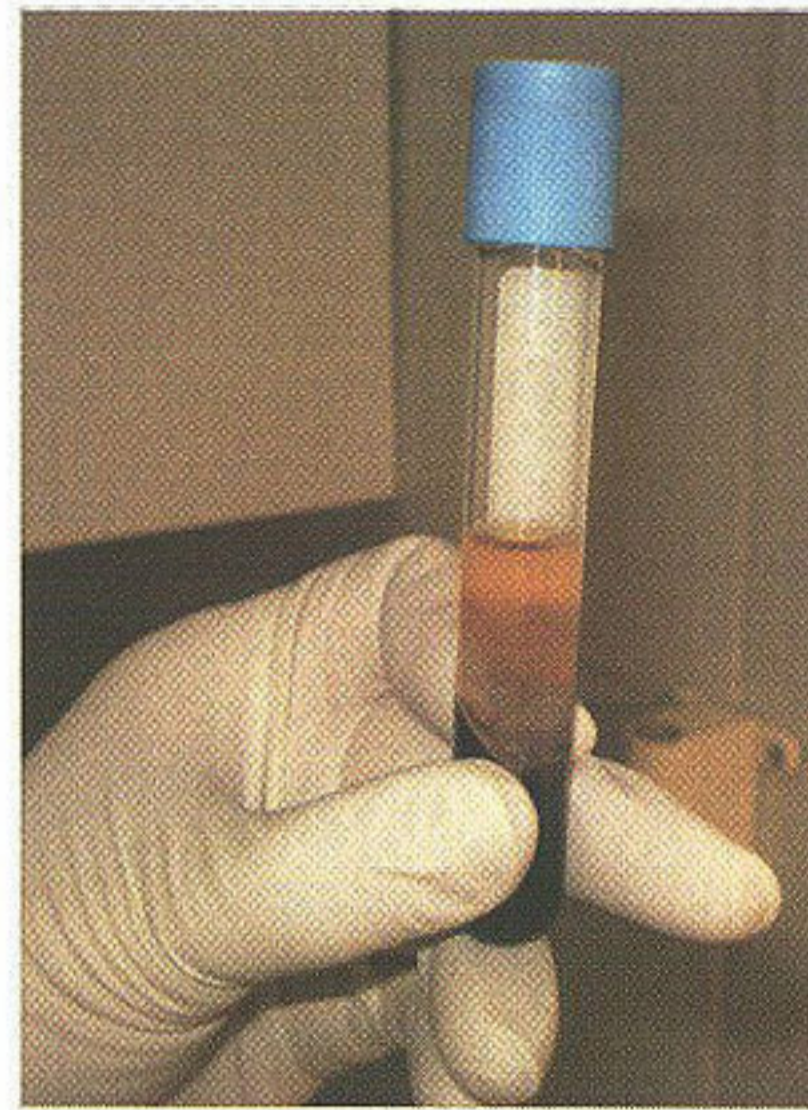
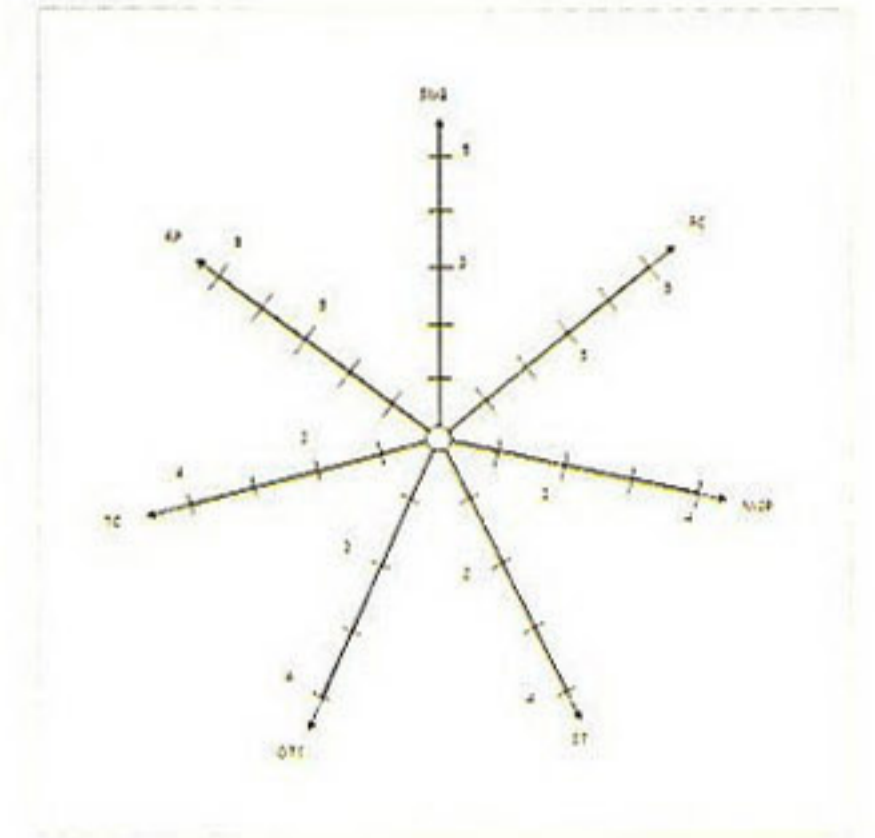
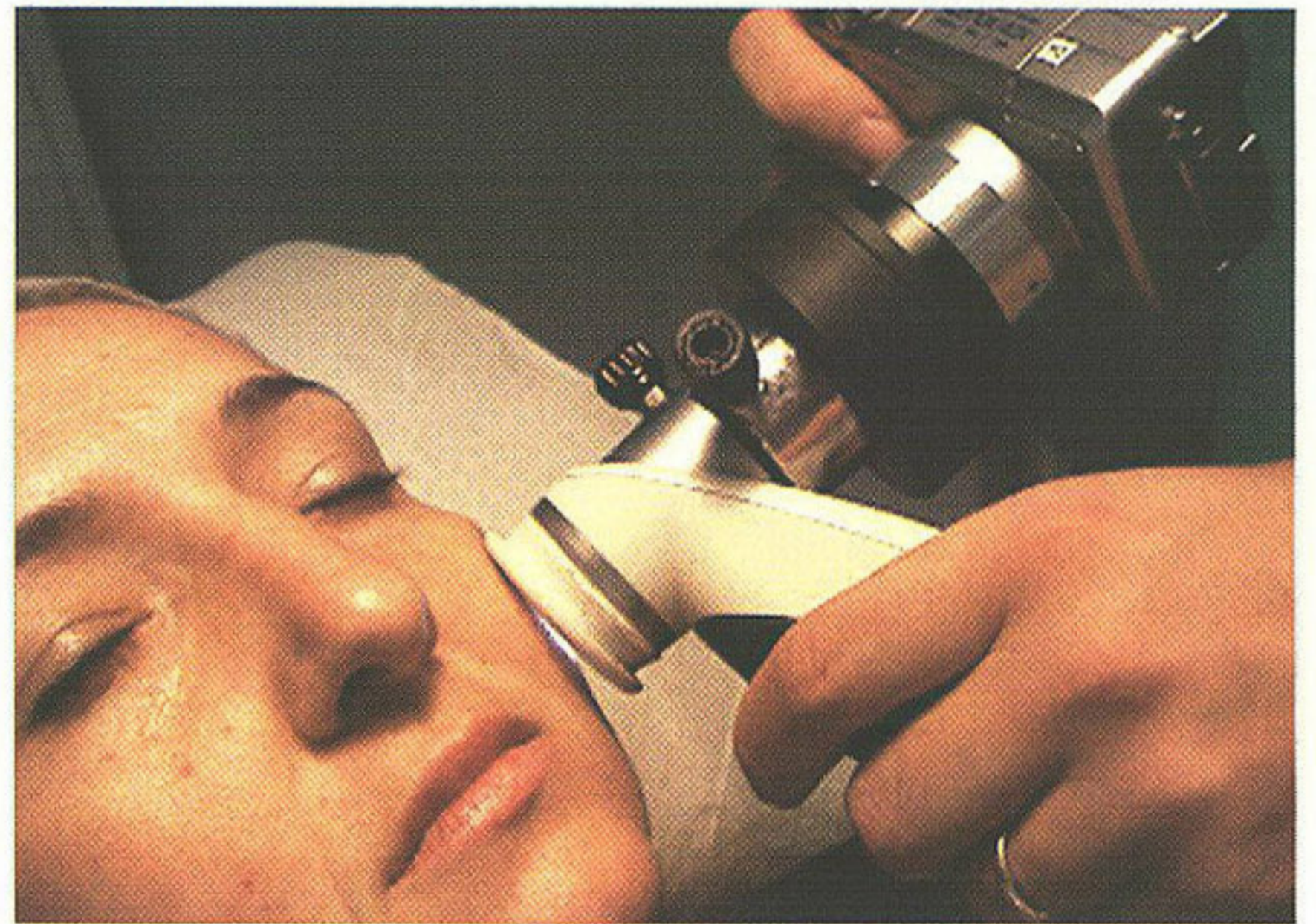
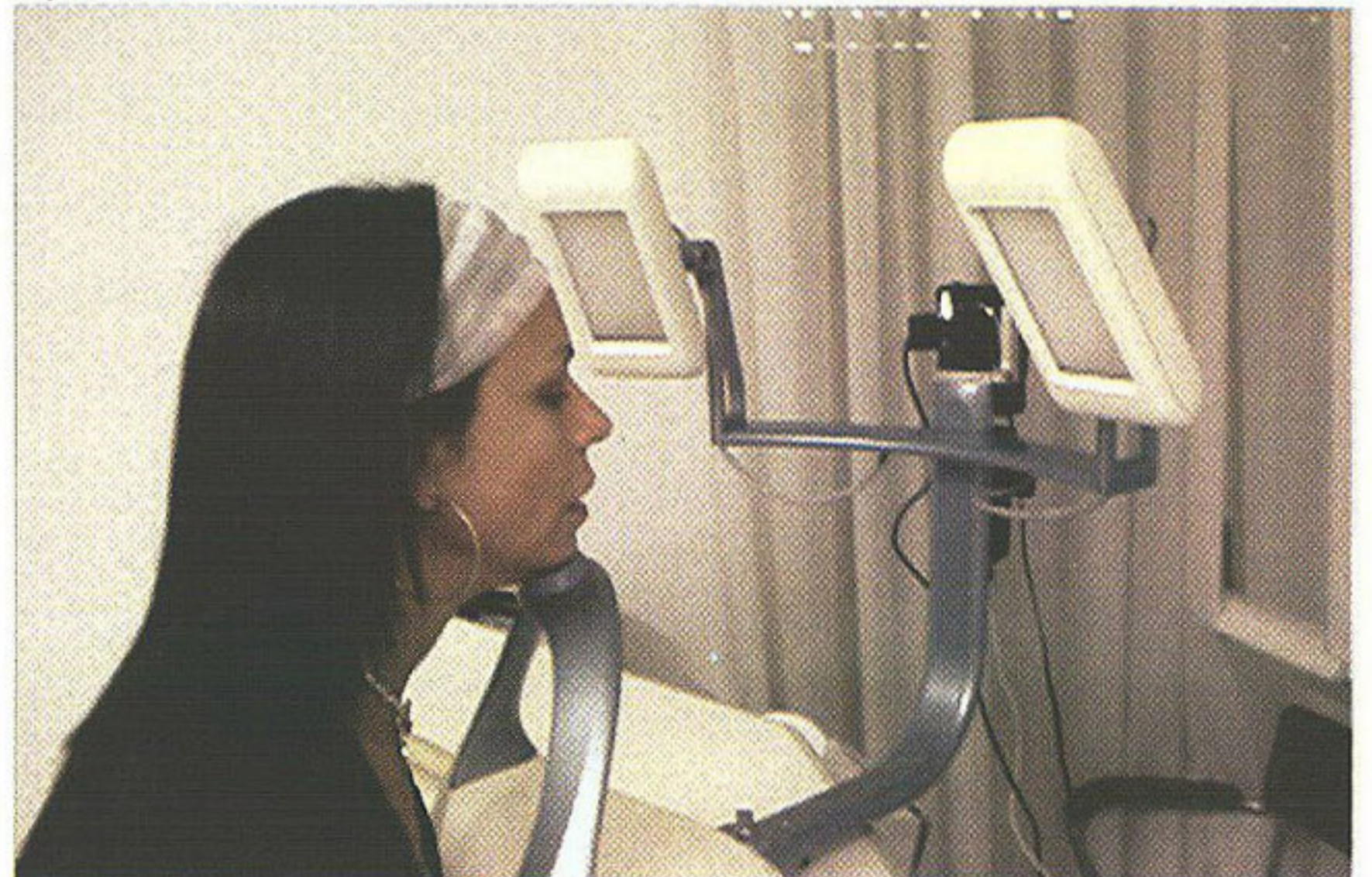
The Personal Folder consists of 10 pages, which include the following: a short presentation and the protocol explanation; the clinical-anamnestical parameters (a short anamnesis, basal hemochrome with platelet count, the contraindications to the treatment [an individual must be in good health and not have any active disease or pre-existing medical conditions]); the "stake-out" of the informed consent to confirm that it has been signed; a short résumé of the side effects observed, the photographic documentation and a special spider (Figure 2) calculated before injecting patients on days 0, 30, 60 and 90; the final spider, with the gap between the initial and final spider, featuring eight parameters scaled from 0 to 4–5 for exact quantification of the defect examined: nasolabial folds (SNG, scale 1–5); snap test to evaluate elasticity (ST, scale 1–4); skin homogeneity and texture (OTC, scale 1–4); cantal periorcular wrinkles (RP, scale 1–5); skin tonicity (TC, scale 1–4); neck wrinkles (RC, scale 1–5); and skin micro-relief (MCR, scale 1–4).

When confronted, the individual parameter results gave an interesting overall picture of the situation or its changing. The folder also contained the Patient's Satisfaction Questionnaire with some final questions related to the treatment and its outcome (Table 1), as well as a doctor's Definitive Graduated Score (DGS) and the informed consent signed by the patients.

The study was photographically documented for results evaluation, using three different cameras: a dermoscope (Linos DermaGenius Basis), connected to a digital camera (Olympus Camedia C-765), outlining the lateral cantus, the cheek and the central part of the neck (Figure 3). The dermoscope photographs were taken prior to the first session and one month after the last session (T90). It also used a common digital camera (Canon Ixus 80IS) respecting the Frankfort plane: profile left/right, 45 degrees left/right and frontal view (5 cm above the head to the décolleté). The photographs were taken at every treatment

TABLE 1.**Spider Improvement Result Per Individual Parameter (%)**

Naso-labial folds	24%
Horizontal neck bands	28%
Skin micro-relief	27%
Snap test	20%
Skin homogeneity and texture	33%
Skin tonicity	22.5%
Periorcular wrinkles (crow's feet lines)	30%

**FIGURE 1.** PRP tubes after centrifugation.**FIGURE 2.** The special spider used to calculate single parameters before and after treatments.**FIGURE 3.** The dermoscope connected with the digital camera.**FIGURE 4.** The static camera for standardized views (Omnia Imaging System).

session (T0, T30 and T60) and one month after the last session (T90). The third camera was a static camera (Figure 4) for standardized views (Omnia Imaging System), connected to a digital camera with dedicated state-of-the-art software. Its facial imaging system allows to view and compare baseline and follow-up images from one or different patients side-by-side on-screen, in order to obtain perfect aligned positions of patients before and after photographs.

The photographs were taken, and the blood samples centrifugally separated, thus obtaining a two-part plasma: the upper part, consisting of 2 mL of platelet-poor plasma (PPP); and the lower part, consisting of 2 mL of platelet-rich plasma (PRP). The 2 mL PPP was first gently aspirated, to avoid its mixing up with the PRP. The residual 2 mL of PRP was subsequently aspirated from each test tube and prepared for activation by calcium chloride in the proportion of 0.1 mL per 0.9 mL of PRP, thus obtaining a 4 mL concentration of activated PRP. In the initial 10 cases, four syringes of 1 mL with a 30 G needle were used; whereas in the following cases a 2 mL syringe with a 30 G needle was used. The PRP solution was finally injected within next seven minutes.

Technique of Injection

Injection points and injected quantities were standardized.⁵ The 4 mL concentrate (2 mL per test tube) was entirely used and administered as follows: 1 mL into the upper third of the face: forehead and crow's feet area (0.5 mL per side); 1 mL into the cheeks (0.5 mL per side); 1 mL into the nasolabial and marionette folds (0.5 mL per side); and 1 mL into the neck (0.5 mL per side).

The injection techniques applied, varied according to the injection location: in the forehead and neck, a 0.1 mL solution was intradermally injected in every site, using a "micro ponfi" technique; in the cantal area, a 0.2 mL solution was administered using a "wave" technique: after an initial ponfo, the needle penetrates into the injected mixture; in the cheek area, a 0.1 mL solution was injected using a "linear retrograde" technique, while pulling the needle slowly backwards; in the nasolabial folds a 0.2/0.3 mL solution was administered using a "linear retrograde and fanning" technique with two or three retrograde injections, called "tunnelling": a back-and-forth movement of the needle which first creates a tunnel, a track and then fills it with the solution. The "tunnelling" technique takes advantage of the restoration of the mild trauma provoked.

Acne scars were treated in two of the patients using an "abundant ponfi" technique (Figure 5). A forehead scar was treated in one of the patients. Treated areas were gently massaged and molded with hydrating cream after the injection. After the treatment the patients returned to normal activities.

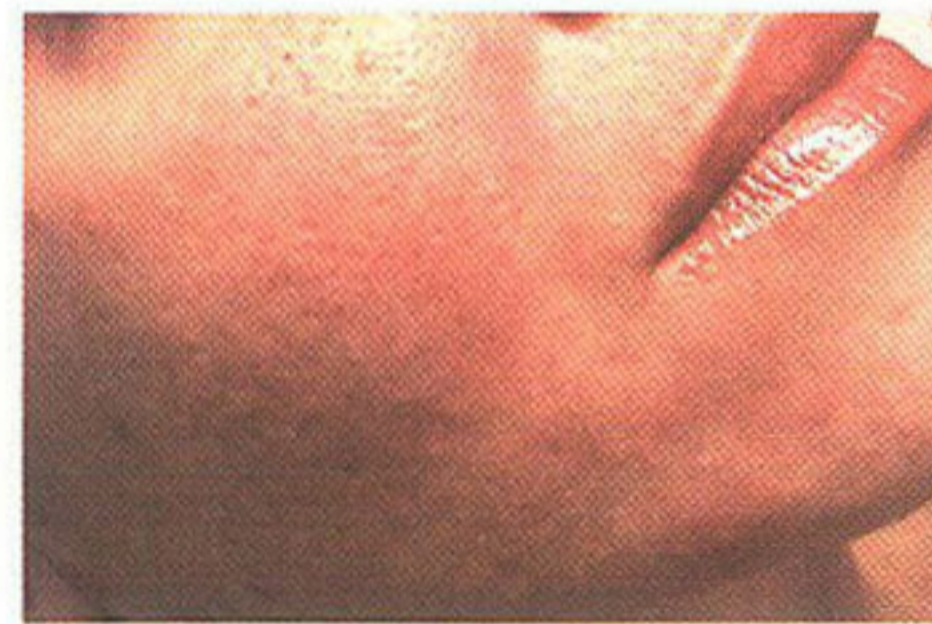
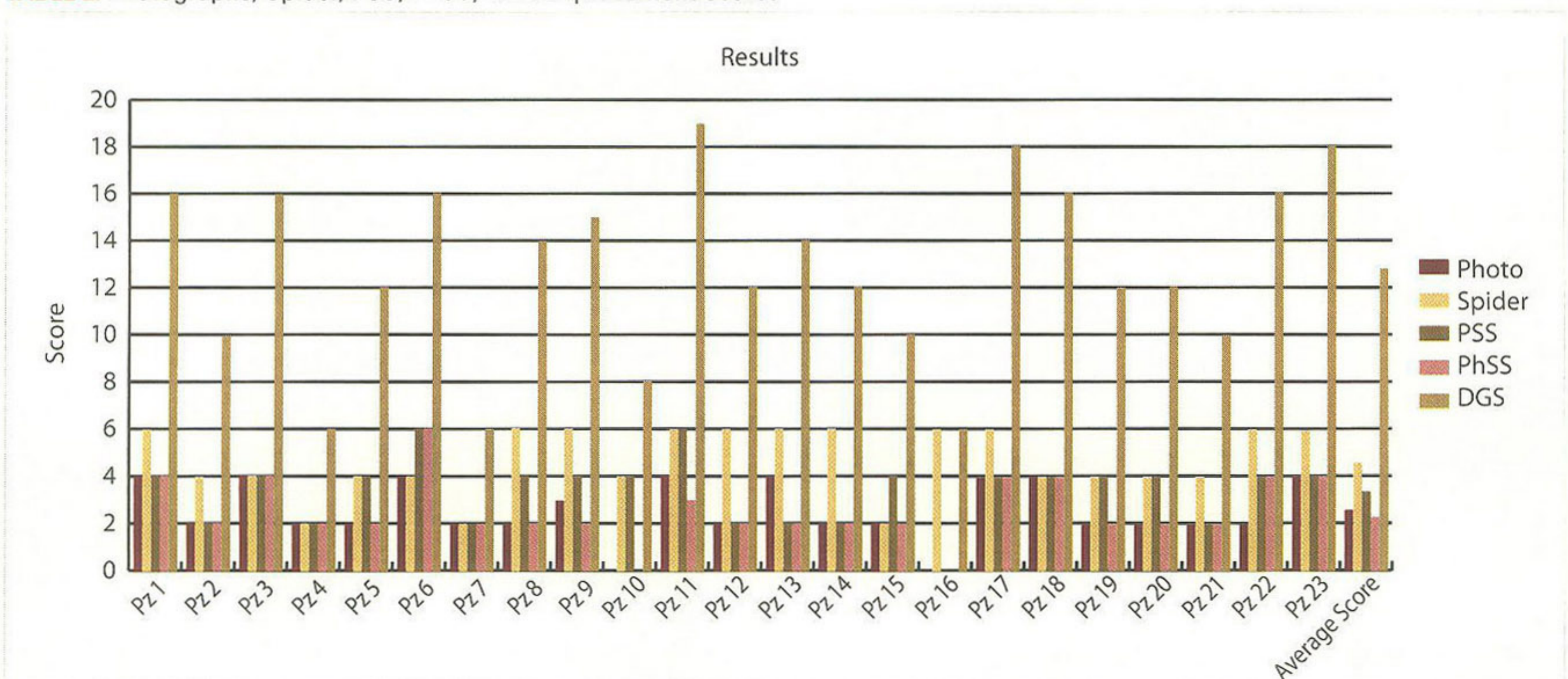


FIGURE 5. Acne scars treated with an "abundant ponfi" technique.

TABLE 2. Photographs, Spider, PSS, PhSS, DGS Improvement Scores



Photographs, Spider, PSS, PhSS improvement scores are: 0=none, 2=mild, 4=good, 6=very good, 8=excellent
The DGS improvement scores are: 0-4=none, 4-8=mild, 8-16=good, 16-24=very good, 24-36=excellent
Legend: PSS=Patient's Satisfaction Score; PhSS=Physician's Satisfaction Score

Side Effects

No serious and persistent side effects were detected. Mild and transient adverse events were observed as follows: 3% of patients experienced well-tolerated bruising/ecchymosis; 70% of patients experienced a burning sensation for about three minutes after injections. This was probably also due to calcium chloride; 80% of patients experienced mild erythema, which resolved without treatment. No serious cases of infection or hematoma were detected.

RESULTS

The results were evaluated one month after the last session (January 2009), as follows: by comparing the pre- and post-improvement photographs taken with the dermoscope, the digital camera and the Omnia Imaging System; by evaluating the spiders improvements; by the final patient's satisfaction questionnaire; and by the physician's impressions.

The improvement result obtained by confronting these four parameters was calculated as follows: 0=no result; 2=moderate result; 4=good result; 6=very good result; 8=excellent result.

Finally, a Definitive Graduated Score (DGS) was found for each patient by adding the final result of each single parameter. The DGS improvement result was calculated as follows: 0–4=none; 4–8=moderate; 8–16=good; 16–24=very good; 24–36=excellent. The results are illustrated in Table 2.

Spider Improvement Results

The method of scoring spider improvements is reported in Table 3. An average 29% improvement was obtained (variable improvement range, 6–50%). The average percentage of improvement was good. The improvement result per individual

TABLE 3.

Method of Scoring Spider Improvement		
Spider Improvement	Result	Score
0	None	0
0–15%	Mild	2
15–30%	Good	4
30–50%	Very good	6
Over 50%	Excellent	8

FIGURE 6. Dermoscope picture before the treatment of a cheek.

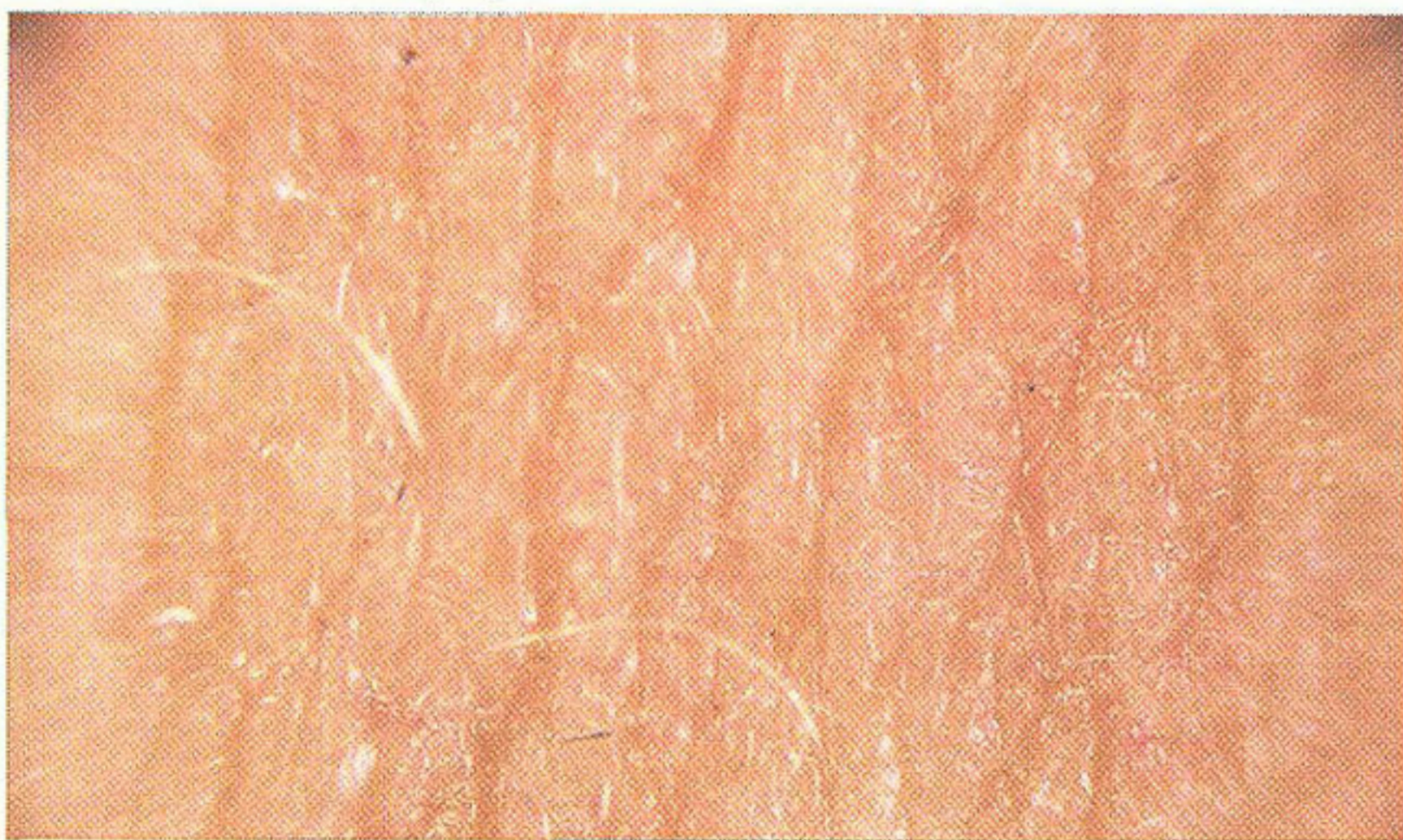


FIGURE 7. Dermoscope picture after the treatment of a cheek.

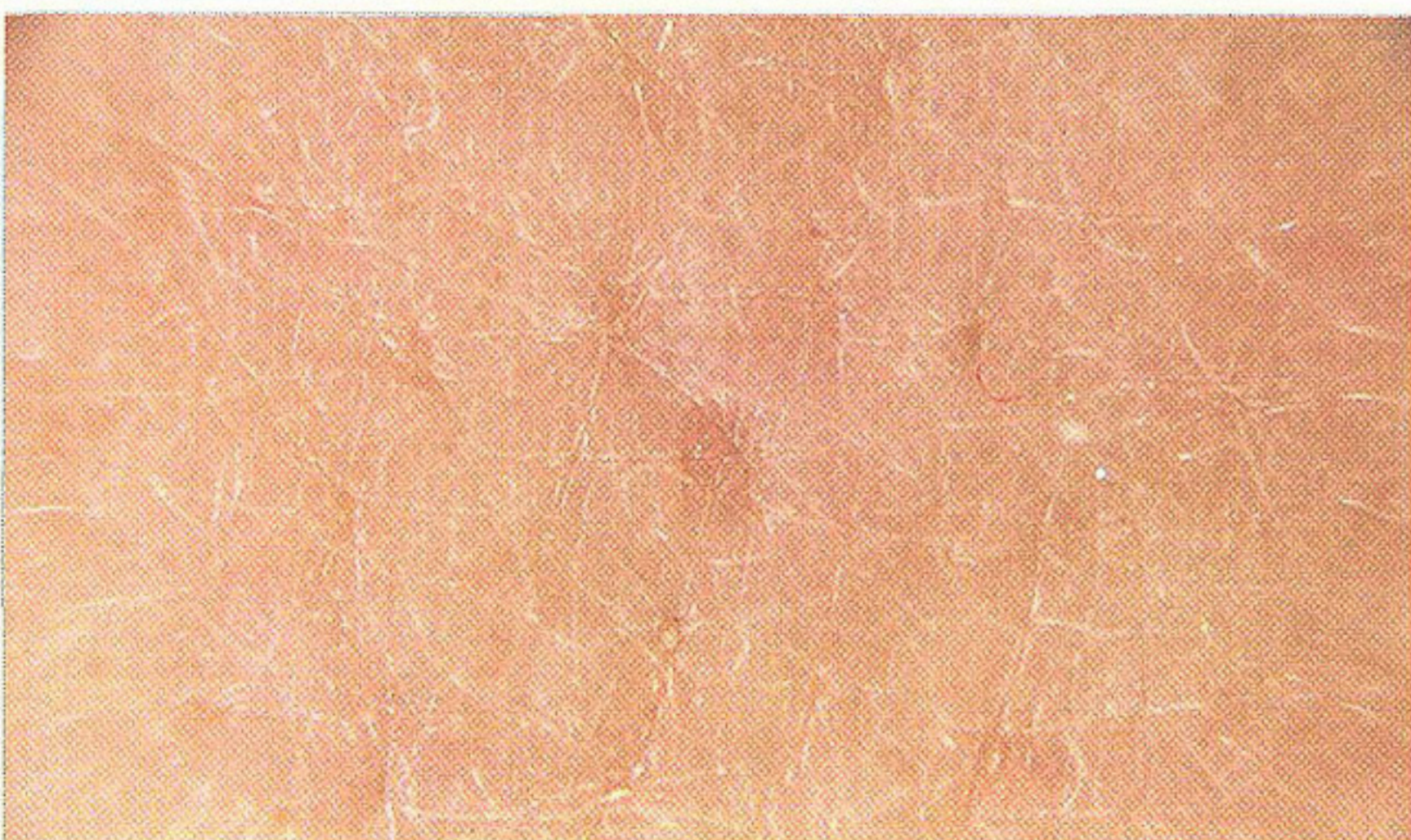

FIGURE 8. Volume increase of nasolabial folds in patient 4: Pre.

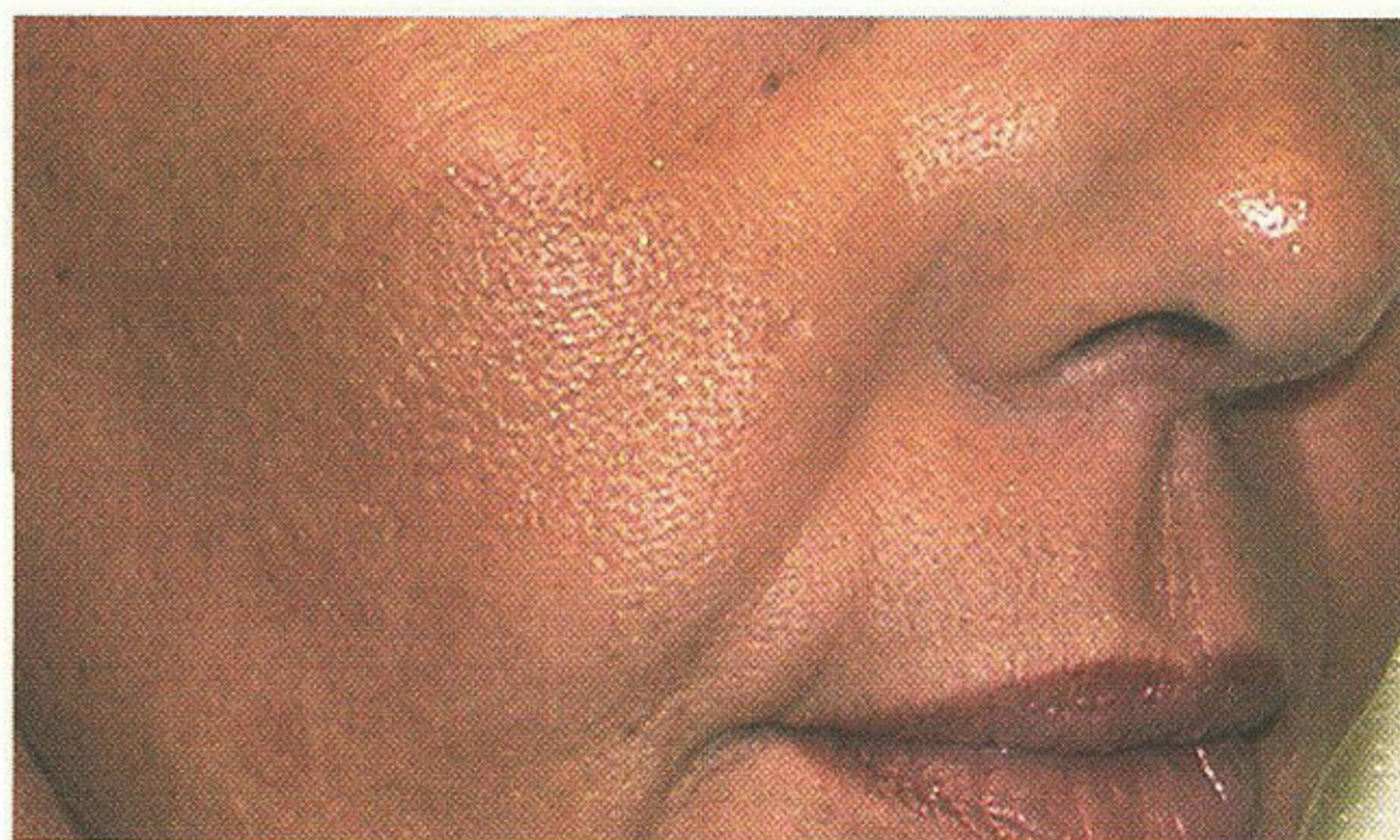


FIGURE 9. Volume increase of nasolabial folds in patient 4: Post.

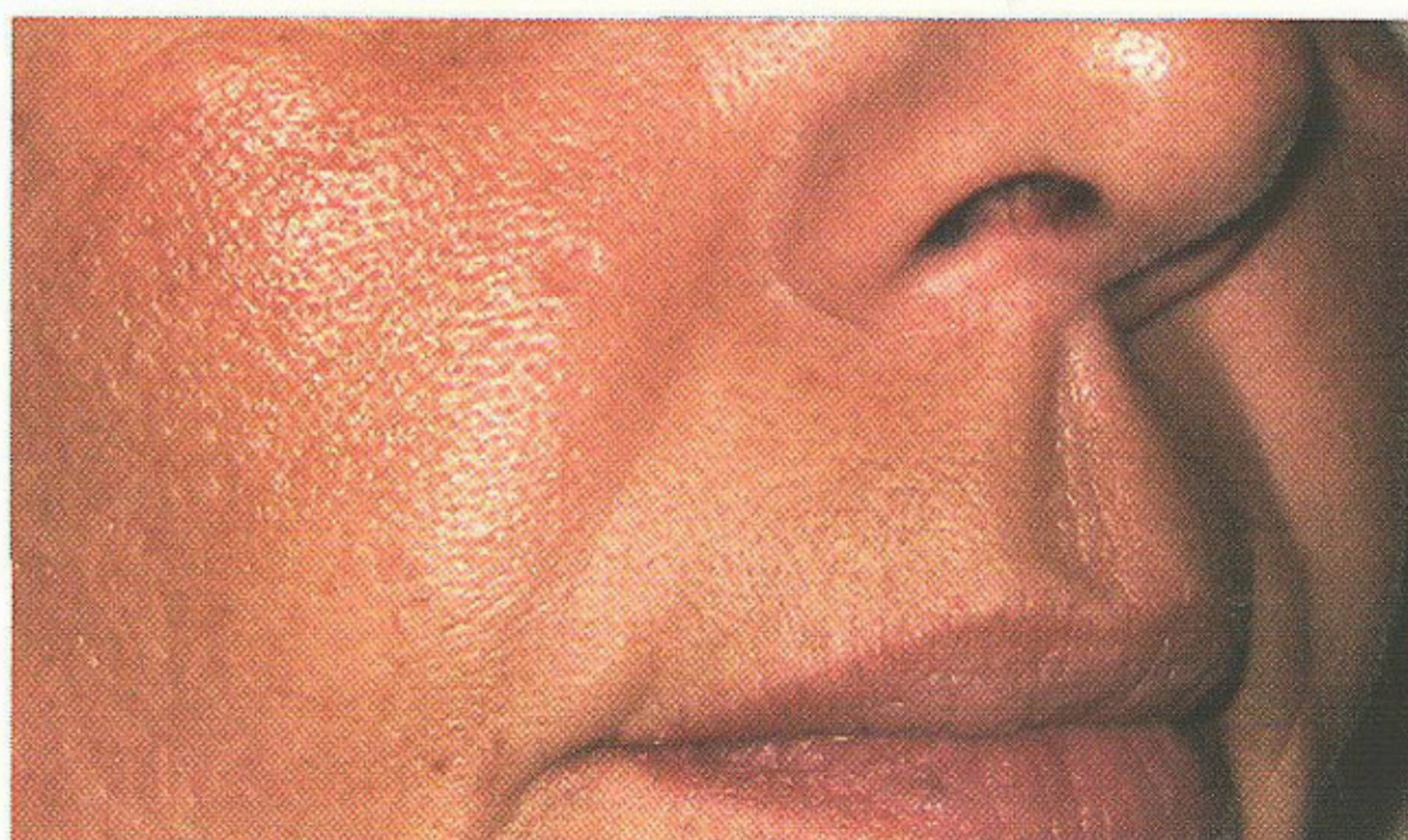
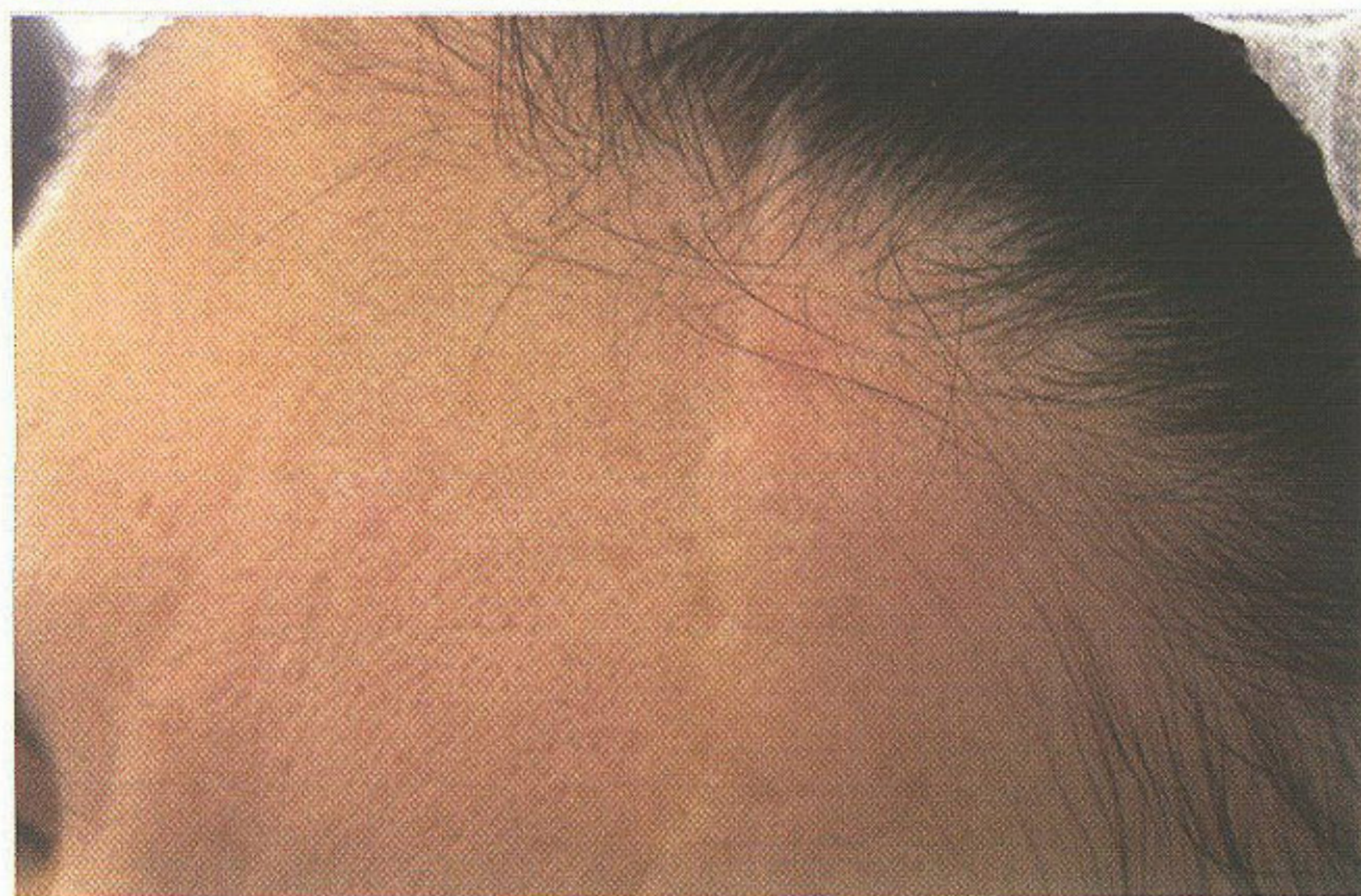
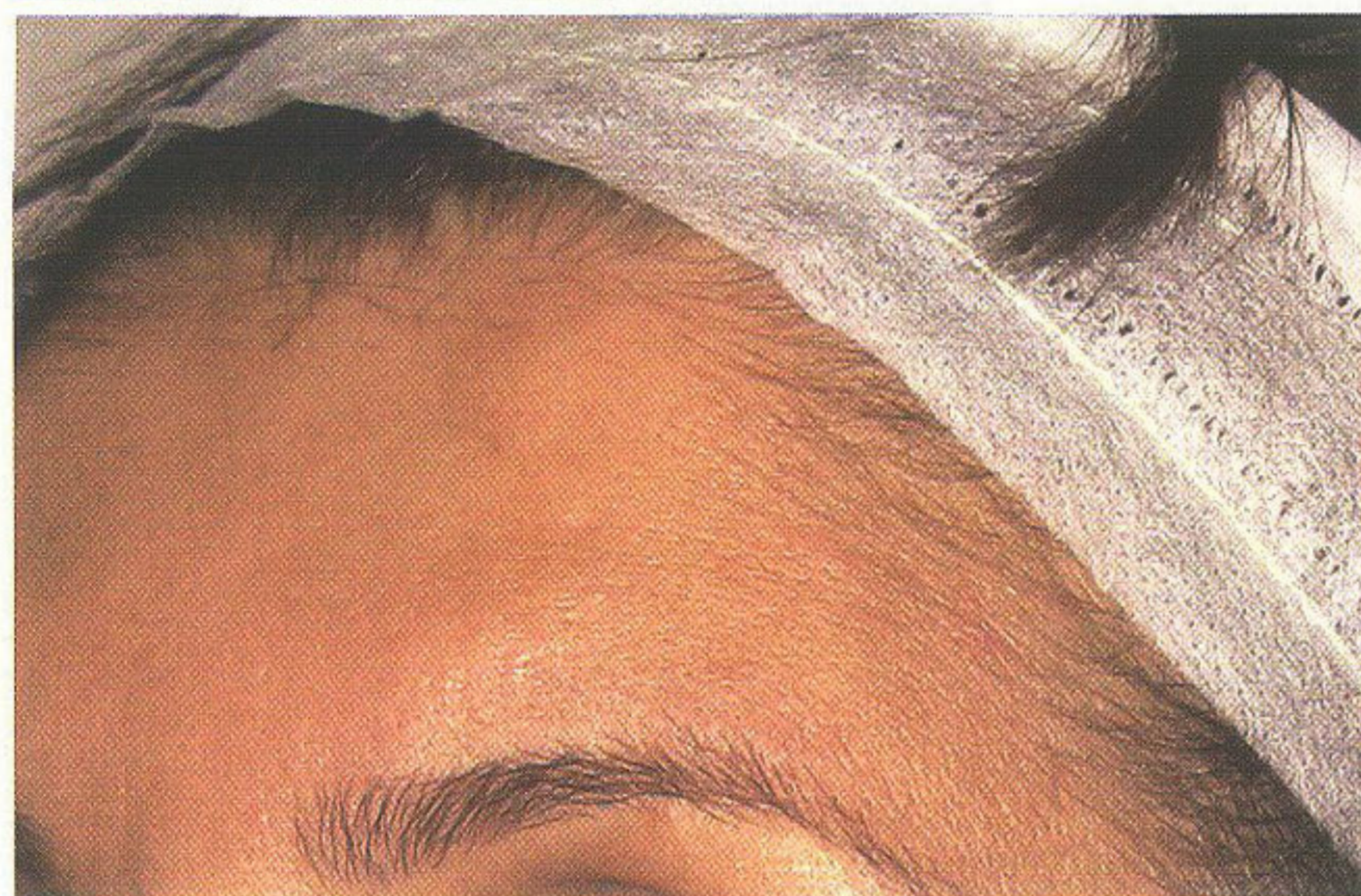


FIGURE 10. Treatment of scars: Pre.**FIGURE 11.** Treatment of scars: Post.

parameter was as follows (Table 1): nasolabial folds (24%); horizontal neck bands (28%); skin micro-relief (27%); snap test (20%); skin omogeneity and texture (33%); skin tonicity (22.5%) and periocular wrinkles (crow's feet lines) (30%). Every patient experienced a significant improvement of the micropigmentation, as well as of skin texture and homogeneity. Besides, as expected, an improvement occurred also for small wrinkles (crow's feet wrinkles and cutaneous micro-relief). The average score for spider improvement was 4.6, ranging from good to very good.

Photograph Results

In most of the patients, a good improvement of skin texture and elasticity was observed and photographically documented using a dermoscope. Figures 6 and 7 show pre- and post-improvement results in cheeks. In addition, a volume increase at the injection site of nasolabial folds was detected in 65% of patients, as shown in Figures 8 and 9. A very interesting result was observed in the treatment of scars: forehead scars almost disappeared after the treatment, as indicated in Figures 10 (pre) and 11 (T130 days). Acne scars were also treated with very good results.

TABLE 4.

Final Patient's Satisfaction Questionnaire

Dear Patient,
Your feedback is very important to us, and we would value a few moments of your time to complete this questionnaire.

Were you familiar with the rejuvenation treatment with platelet-rich plasma (PRP) prior to the treatment?

YES = 60.8% NO = 39.2%

Please rate the accuracy of overall information and instructions on the treatment provided by your physician:

Poor	= 0%
Average	= 8.6%
Good	= 30.4%
Excellent	= 61%

Were you satisfied with the overall quality of the treatment?

YES = 100% NO = 0%

Do you think your general look has improved?

YES = 87% NO = 13%

Do you think your wrinkles have improved?

YES = 52% NO = 48%

Do you think your skin tonicity has improved?

YES = 82.6% NO = 17.4%

Please rate your degree of satisfaction with the treatment:

No improvement	= 4.3%
Mild improvement	= 30.4%
Good improvement	= 61%
Very good improvement	= 4.3%
Excellent improvement	= 0%

The results illustrated in the photographs taken with the Omnia Imaging System was poor on some patients, due to incompetence in the use of the system, which required some training. The photographs were out of focus, patients' positions were not perfectly aligned and the chin rest position was altered. Further study in the use of the Omnia Imaging System needs to be carried out, the technique being very promising. The simulation software features expanded capability with multiple camera and lighting options, allowing low lighting application and long exposition times. The final average improvement of the photographs result was 2.6, ranging from moderate to good.

Patient's Satisfaction Score (PSS)

An anonymous record was filled in by the patients and it can be seen in Table 4. Overall appreciation was expressed by the patients for the ease of use and safety of the technique. The result obtained is partly attributable to factors, which are not always objectively demonstrable. A final patient's satisfaction

score was calculated, its final average improvement was 3.4, ranging from moderate to good (Table 5).

Doctor's Satisfaction Score (DSS)

The result provided by the physician who administered the treatment was obtained considering the photographs evaluation, the patient examination and the general aspects connected with the application of the technique: time, cost and difficulties involved in its preparation. In this context, it should be noticed that the preparation of the technique required more time than in similar preparations. Overall, the degree of satisfaction shown in the final doctor's satisfaction score was inferior to the one reported in the patient's satisfaction score. The average result was 2.2, ranging from moderate to good. Very good or excellent results were never obtained.

Definitive Graduated Score (DGS)

A definitive graduated score was calculated by comparing the spider improvement score, the pre- and post-improvement photographs, the patient's satisfaction score and the doctor's satisfaction score. The DGS result was good (average 12.8), as shown in Table 6. In this context, it should be stressed the discrepancy noticed between the individual patient's satisfaction score, which was good in most patients, and the doctor's satisfaction score, which was relatively less good and not always objectively quantifiable. The very good results reported in the individual patient's satisfaction score seem to suggest that the doctor's and patient's degree of satisfaction with the treatment differ in the fact that patients detected objective improvements also on an early stage. It is also important to emphasize

the high satisfaction rate with most patients reporting general aspects of rejuvenation: improvement of the overall texture health and appearance of the skin and correction of moderate facial wrinkles. This aspect determined the high DGS score. The very good result on acne and scars of different nature should be stressed here, although more time is required for final result appreciation.

CONCLUSION

Face and neck revitalization with PRP is a promising, easy-to-use technique, performing favorably in all small skin wrinkles, as well as in skin texture and elasticity. Good results were also observed in skin homogeneity. No serious and persistent side effects were detected. The technique was well tolerated. Objective clinical results were good. Patient's satisfaction was very high. The technique's exact mechanism of action has not yet been entirely clarified. Although the method needs further validations, initial results are encouraging and promising, particularly for those cases in which reparative processes are required.

ACKNOWLEDGEMENTS

The authors would like to thank Drs. Ilaria Mercuriali and Tiziana Piani for their scientific and practical help.

DISCLOSURES

The authors have no disclosures to state. No payment has been made by any company. Regen Lab (Geneva Suisse) has given the kits (tubes and blood kits) for this work free.

REFERENCES

1. Aleksic Z. Clinical impact of platelet rich plasma in treatment of gingival recessions. *Srp Arh Celok Lek.* 2008;136(3-4):95-103.
2. Anitua E. The use of plasma-rich in growth factors (Prgf) in oral surgery. *Pract Proced Aesthet Dent.* 2001;13(6):487-493.
3. Bashutski JD, Wang HL. Role of platelet-rich plasma in soft tissue root-coverage procedures: A review. *Quintessence Int.* 2008;39(6):473-483.
4. Ebisawa K. Cell therapy for facial anti-aging. *Med J Malaysia.* 2008;63 Suppl A:41.
5. Garcia VG, Albandea GNA. Tratamiento del envejecimiento cutáneo mediante bioestimulación: Utilización de factores de crecimiento autólogos. *Int J Cosm Med Surg.* 2007;9-2:11-13.
6. Hammond JW. Use of autologous platelet-rich plasma to treat muscle strain injuries. *Am J Sports Med.* 2009;37(6):1135-1142.
7. Henderson JL. The effects of autologous platelet gel on wound healing. *Ear Nose Throat J.* 2003;82(8):598-602.
8. Kakudo N. Proliferation-promoting effect of platelet-rich plasma on human adipose-derived stem cells and human dermal fibroblasts. *Plast Reconstr Surg.* 2008;122(5):1352-1360.
9. Mehta S. Platelet rich concentrate: Basic science and current clinical applications. *J Orthop Trauma.* 2008;22(6):432-438.
10. Rutkowski JL. Analysis of a rapid, simple and inexpensive technique used to obtain platelet-rich plasma for use in clinical practice. *J Oral Implantol.* 2008;34(1):25-33.

TABLE 5.

Percent of Patients Who Declared a Particular Result and Method of Scoring PSS Improvement

% of Patients	Result	Score
4.3	None	0
30.4	Mild	2
61	Good	4
4.3	Very good	6
0	Excellent	8

TABLE 6.

Method of Scoring DGS Improvement

% of Patients	Result	Score
0	None	0-4
17	Mild	4-8
70	Good	9-16
13	Very good	17-24
0	Excellent	25-36

11. Sanchez M, Azofra J, Anitua E, et al. Plasma-rich in growth factors to treat an articular cartilage avulsion: A case report. *Med Sci Sports Exerc.* 2003;35(10):1648-1652.
12. Simman R. Role of platelet-rich plasma in acceleration of bone fracture healing. *Ann Plast Surg.* 2008;61(3):337-344.
13. Toscano N. Surgical considerations in the use of platelet-rich plasma. *Compend Contin Educ Dent.* 2008;29(3):182-185.
14. Wu W. Platelet-rich plasma—A promising cell carrier for micro-invasive articular cartilage repair. *Med Hypotheses.* 2009;72(4):455-457.
15. Anderson KW, Baker SR. Advances in facial rejuvenation surgery. *Curr Opin Otolaryngol Head Neck Surg.* 2003;11(4):256-260.
16. Welsh WJ. Autologous platelet gel. Clinical function and usage in plastic surgery. *Cosmetic Dermatology.* 2000;13-18

ADDRESS FOR CORRESPONDENCE

Redaelli Alessio, MD

Visconti di Modrone Medical Center

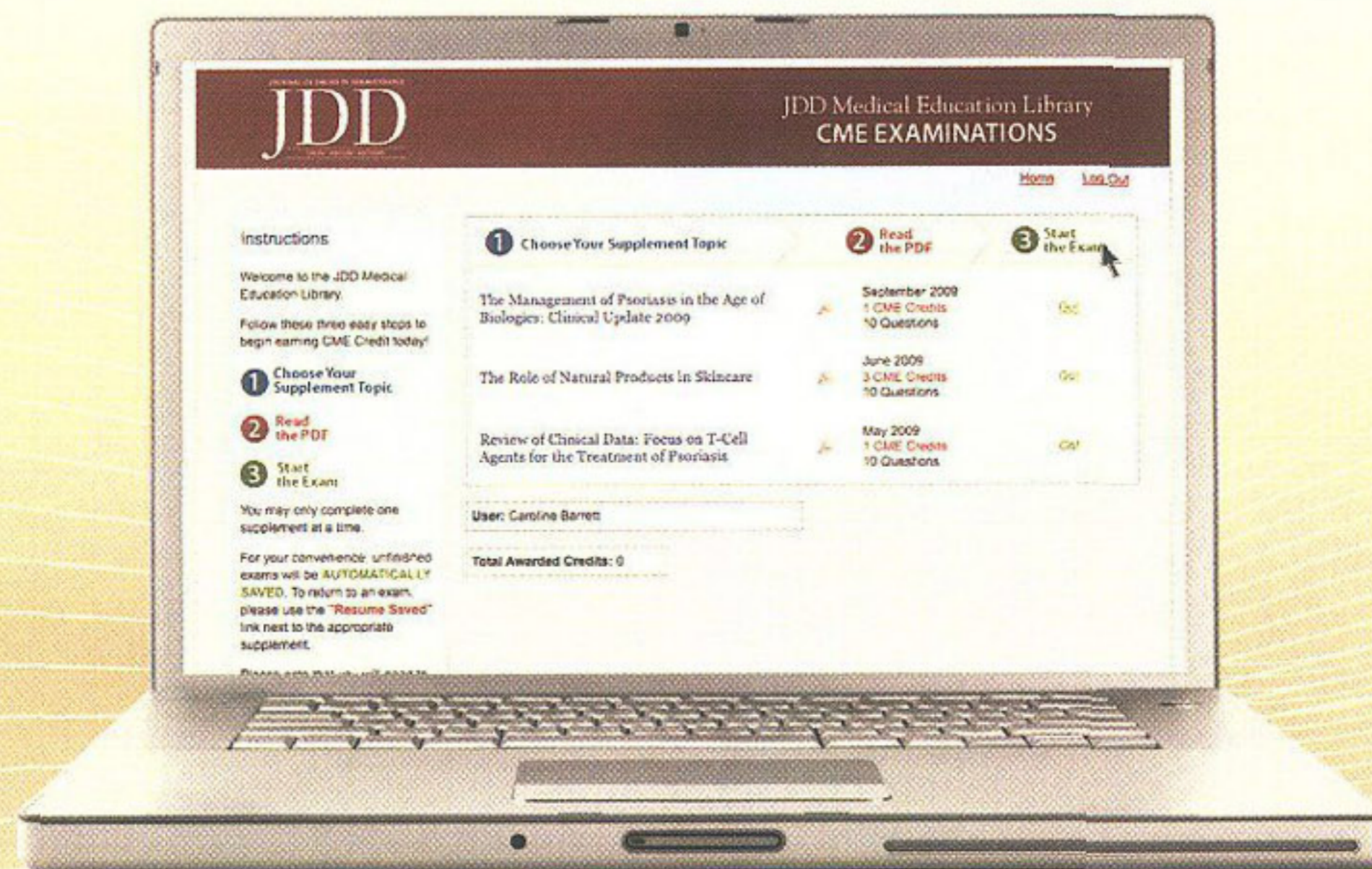
Via Visconti di Modrone 7

20121 Milan, Italy

Phone and Fax: 0039 02 9818775

E-mail:mail@docredaelli.com

CME Credits available at JDDonline.com

 **Go Green, Go Online!**


EXCELLENCE THROUGH PEER-REVIEW